

2015

# Transesophageal echocardiogram: Accurate enough to make definitive clinical decisions related to endocarditis

Brian Jackson

Wayne State University, marsonbus77@gmail.com

Paul Thomas

Oakwood Hospital and Medical Center, paulthomas2013@gmail.com

Tiffany Dehondt

Wayne State University, tdehondt@med.wayne.edu

Leanne Swiderski


Oakwood Hospital and Medical Center, leanne.swiderski@oakwood.org

Rachel Fuller

Wayne State University, rfuller@med.wayne.edu

*See next page for additional authors*

Follow this and additional works at: <https://digitalcommons.wayne.edu/crp>

 Part of the [Medical Education Commons](#), and the [Translational Medical Research Commons](#)

## Recommended Citation

Jackson B, Thomas P, Dehondt T, Swiderski L, Fuller R, Raychouni A. Transesophageal echocardiogram: Accurate enough to make definitive clinical decisions related to endocarditis. *Clin. Res. Pract.* 2015;1(1):eP1007. doi: [10.22237/crp/1429187721](https://doi.org/10.22237/crp/1429187721)

This Critical Analysis is brought to you for free and open access by the Open Access Journals at DigitalCommons@WayneState. It has been accepted for inclusion in Clinical Research in Practice: The Journal of Team Hippocrates by an authorized editor of DigitalCommons@WayneState.

---

# Transesophageal echocardiogram: Accurate enough to make definitive clinical decisions related to endocarditis

## **Authors**

Brian Jackson, Paul Thomas, Tiffany Dehondt, Leanne Swiderski, Rachel Fuller, and Amal Raychouni

# Transesophageal echocardiogram: Accurate enough to make definitive clinical decisions related to endocarditis

BRIAN JACKSON, Wayne State University, Detroit, MI  
PAUL THOMAS, Oakwood Hospital and Medical Center, Dearborn, MI  
TIFFANY DEHONDT, Wayne State University, Detroit, MI  
LEANNE SWIDERSKI, Oakwood Hospital and Medical Center, Dearborn, MI  
RACHEL FULLER, Wayne State University, Detroit, MI  
AMAL RAYCHOUNI, Oakwood Hospital and Medical Center, Dearborn, MI

**ABSTRACT** A critical appraisal and clinical application of: Daniel WG, Mugge A, Martin RP, et al. Improvement in the diagnosis of abscesses associated with endocarditis by transesophageal echocardiography. *N Engl J Med.* 1991 Mar 21;324(12):795-800. doi: [10.1056/NEJM199103213241203](https://doi.org/10.1056/NEJM199103213241203)

**Keywords:** transesophageal echocardiography, TEE, abscesses, endocarditis

## Clinical Context

During rounds the primary care team discussed a 26 year old woman with a past medical history of MRSA infection and IV drug use who presented with subjective fever, malaise, vision changes, chills, night sweats, chest pain, shortness of breath and new onset rash with excoriations extending over the legs, arms, back, and face. The rash was initially described as painful without pruritus. One isolated papule located on the right palm developed during the hospital stay and was subjectively different than the other papules. Additionally, she became concerned of new onset pain in the left knee that limited range of motion with a palpable effusion. At that time we decided to complete a full social history; our patient disclosed that she has shared needles with her fiancée who is hepatitis C positive. This historical framework fulfilled two minor Duke criteria<sup>1</sup> (immunologic phenomena and IV drug abuse) and three minor Jones criteria<sup>2</sup> (fever, arthralgia, and leukocytosis [max 13.0] ESR/CRP), raising our suspicion of endocarditis or associated abscess despite negative cardiovascular physical exam findings.

In order to determine a pretest probability, our team began with each of our nine members independently determining an odds percentage based on their clinical experience. The team members then revealed their independent probabilities to the group. The outliers were removed, the remaining probabilities averaged, and the final number discussed. A consensus emerged and our team assigned a pretest probability of 20% for endocarditis with associated abscess in this patient. Based on previous experiences, the team concluded that a transesophageal echocardiogram (TEE) would be required, but were unable to provide evidence that would justify its application in this clinical scenario.

BRIAN JACKSON, TIFFANY DEHONDT, and RACHEL FULLER are fourth year medical students at Wayne State University School of Medicine. PAUL THOMAS is a second year family medicine resident at Oakwood Hospital and Medical Center. LEANNE SWIDERSKI and AMAL RAYCHOUNI are senior family medicine residents at Oakwood Hospital and Medical Center.

## Clinical Question

How useful is a TEE in helping our patients obtain diagnostic certainty regarding a suspected endocarditis with associated abscess?

## Research Article

Daniel WG, Mugge A, Martin RP, et al. Improvement in the diagnosis of abscesses associated with endocarditis by transesophageal echocardiography. *N Engl J Med.* 1991 Mar 21;324(12):795-800. doi: [10.1056/NEJM199103213241203](https://doi.org/10.1056/NEJM199103213241203)

## Literature Review

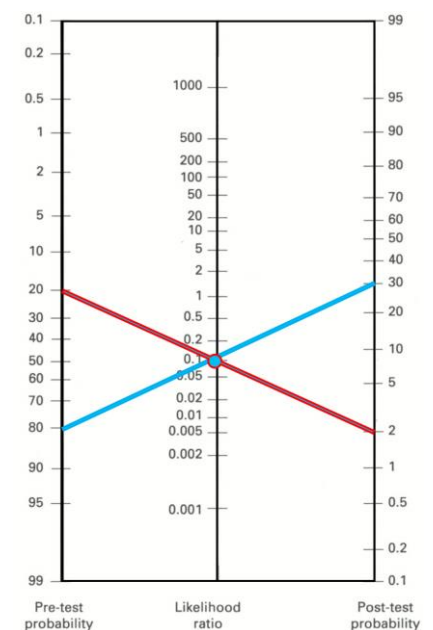
An UpToDate and Google Scholar search using the terms “transesophageal echocardiography,” “endocarditis abscess,” and “endocarditis diagnosis” was performed, and results were filtered to include only prospective trials, in order to find the most relevant articles surrounding TEE and its diagnostic value in endocarditis with abscess. We found multiple studies that compared transthoracic echocardiograms and TEE’s, with nearly all demonstrating the vast superiority of TEE in diagnosis of endocarditis<sup>3-7</sup>. Some studies even suggested that TEE should be the initial diagnostic test of choice when suspecting endocarditis with prosthetic valves or suspicion of vegetations<sup>7,8</sup>. Given the significant mortality associated with endocarditis<sup>9</sup>, the fact that up to 30 percent of patients with endocarditis can have associated abscesses<sup>10</sup>, and the fact that those patients with associated abscesses have more severe clinical courses<sup>10</sup>, we sought one diagnostic test supported by a strong prospective study that would allow us to rule out endocarditis and associated abscesses. This led us to the research article chosen for appraisal.

## Critical Appraisal

In this blinded SORT level 2 study, TEE was compared against direct visualization during surgery or at autopsy, which are the gold standards for diagnosis of endocarditis-associated abscess. Two physicians reviewed the echocardiogram images independently: one who performed the TEE and a second physician. Since both physicians reviewed the images prior to surgery or autopsy, they were blinded to the results of the gold standard. If the two physician reviewers initially disagreed, they then reviewed the images together and reached a consensus. Although this does not represent the strongest protocol in terms of a blinded study, it may be more representative of real life situations in which observers often discuss a medical case and come to an agreement.

We felt that the setting for the study, the study size ( $n = 118$ ) and the patient filters were appropriate when compared to our patient base. Patients in the study met the inclusion criteria of having acute infective endocarditis with or without perivalvular abscess at the time of surgery or autopsy, and of having undergone TEE within seven days prior to surgery or death. Patients were excluded who were found to have abscesses on TEE, but were then treated medically and did not undergo surgery or autopsy. Excluding these patients may have caused the population in the study to differ from the general patient population with endocarditis. However, we also felt that excluding these patients served to strengthen the study because it excluded evidence that lacked diagnosis of the disease by the gold standard.

One concern we identified with the methods of this study is that the interpretation of the data was based on having found 46 abscesses in 44 of 118 patients at the time of surgery or autopsy. In our analysis of the study, we chose to calculate the test characteristics based on the number of patients, given that our original clinical question was how useful the TEE was in evaluating an individual patient. Pragmatically, regardless of the number of abscesses found on TEE, the patient centered treatment remains the same; the fact that 2 patients in this study had more than one abscess does not change their management. Therefore, using these values, we calculated that TEE had a sensitivity of 90.9% and a specificity of 94.6% for the detection of endocarditis abscesses. Based on this, the positive likelihood ratio was calculated to be 16.8 and the negative likelihood ratio was calculated to be 0.10, making TEE for the diagnosis of abscesses associated with endocarditis very useful in clinical decision-making.



**Figure 1.** Fagan nomogram of TEE depicting pre- and post-test probability with calculated likelihood ratio of 0.1.

## Clinical Application

Based on the patient's clinical scenario, it was estimated that there was a 20% chance of endocarditis with abscess. After critically appraising this article, TEE emerged as the best diagnostic test to guide our management for our patient, as the sensitivity is high relative to other options. The patient's TEE was negative, allowing us to calculate a 2% chance of having endocarditis with associated abscess using a Fagan nomogram<sup>11</sup> (see: Figure 1, red line). This post-test probability allowed our team to discharge the patient rather than continuing observation or initiating treatment for endocarditis. Ordering any other diagnostic test may have extended hospital stay and increased cost, without yielding any additional information regarding our patient's condition.

If our patient had an 80% pretest probability for endocarditis with abscess, a negative TEE would have given us post-test probability of 29% using the Fagan nomogram<sup>11</sup> (see: Figure 1, blue line). In that case, it may have been reasonable to keep the patient for observation rather than discharging her.

The three take home points from this article are: 1.) TEE is an excellent tool for diagnosing endocarditis and associated abscess in cases where clinical uncertainty exists. 2.) In our future careers, we will use the TEE as our test of choice when considering a diagnosis of endocarditis and associated abscess. 3.) Our colleagues must know of the utility of the TEE in diagnosing abscesses associated with endocarditis.

## References

1. Durack DT, Lukes AS, Bright DK. New criteria for diagnosis of infective endocarditis: utilization of specific echocardiographic findings. Duke Endocarditis Service. *Am J Med.* 1994 Mar;96(3):200-209. doi: [10.1016/0002-9343\(94\)90143-0](https://doi.org/10.1016/0002-9343(94)90143-0)
2. Guidelines for the diagnosis of rheumatic fever. Jones Criteria, 1992 update. Special Writing Group of the Committee on Rheumatic Fever, Endocarditis, and Kawasaki Disease of the Council on Cardiovascular Disease in the Young of the American Heart Association. *JAMA.* 1992 Oct 21;268(15):2069-2073. doi: [10.1001/jama.1992.03490150121036](https://doi.org/10.1001/jama.1992.03490150121036).
3. Shively BK, Gurule FT, Roldan CA, Leggett JH, Schiller NB. Diagnostic value of transesophageal compared with transthoracic echocardiography in infective endocarditis. *J Am Coll Cardiol.* 1991 Aug;18(2):391-397. doi: [10.1016/0735-1097\(91\)90591-v](https://doi.org/10.1016/0735-1097(91)90591-v)
4. Birmingham GD, Rahko PS, Ballantyne F, 3rd. Improved detection of infective endocarditis with transesophageal echocardiography. *Am Heart J.* 1992 Mar;123(3):774-781. doi: [10.1016/0002-8703\(92\)90519-2](https://doi.org/10.1016/0002-8703(92)90519-2)
5. Blumberg EA, Karalis DA, Chandrasekaran K, et al. Endocarditis-associated paravalvular abscesses. Do clinical parameters predict the presence of abscess? *Chest.* 1995 Apr;107(4):898-903. doi: [10.1378/chest.107.4.898](https://doi.org/10.1378/chest.107.4.898)
6. Reynolds HR, Jagen MA, Tunick PA, Kronzon I. Sensitivity of transthoracic versus transesophageal echocardiography for the detection of native valve vegetations in the modern era. *J Am Soc Echocardiogr.* 2003 Jan;16(1):67-70. doi: [10.1067/mje.2003.43](https://doi.org/10.1067/mje.2003.43)
7. Kini V, Logani S, Ky B, et al. Transthoracic and transesophageal echocardiography for the indication of suspected infective endocarditis: vegetations, blood cultures and imaging. *J Am Soc Echocardiogr.* 2010 Apr;23(4):396-402. doi: [10.1016/j.echo.2009.12.017](https://doi.org/10.1016/j.echo.2009.12.017)
8. Shapiro SM, Young E, De Guzman S, et al. Transesophageal echocardiography in diagnosis of infective endocarditis. *Chest.* 1994 Feb;105(2):377-382. doi: [10.1378/chest.105.2.377](https://doi.org/10.1378/chest.105.2.377)
9. Cosmi JE, Tunick PA, Kronzon I. Mortality in patients with paravalvular abscess diagnosed by transesophageal echocardiography. *J Am Soc Echocardiogr.* 2004 Jul;17(7):766-768. doi: [10.1016/j.echo.2004.03.026](https://doi.org/10.1016/j.echo.2004.03.026)
10. Arnett EN, Roberts WC. Valve ring abscess in active infective endocarditis. Frequency, location, and clues to clinical diagnosis from the study of 95 necropsy patients. *Circulation.* 1976 Jul;54(1):140-145. doi: [10.1161/01.CIR.54.1.140](https://doi.org/10.1161/01.CIR.54.1.140)
11. Fagan TJ. Letter: Nomogram for Bayes theorem. *N Engl J Med.* 1975 Jul 31;293(5):257. doi: [10.1056/NEJM197507312930513](https://doi.org/10.1056/NEJM197507312930513)